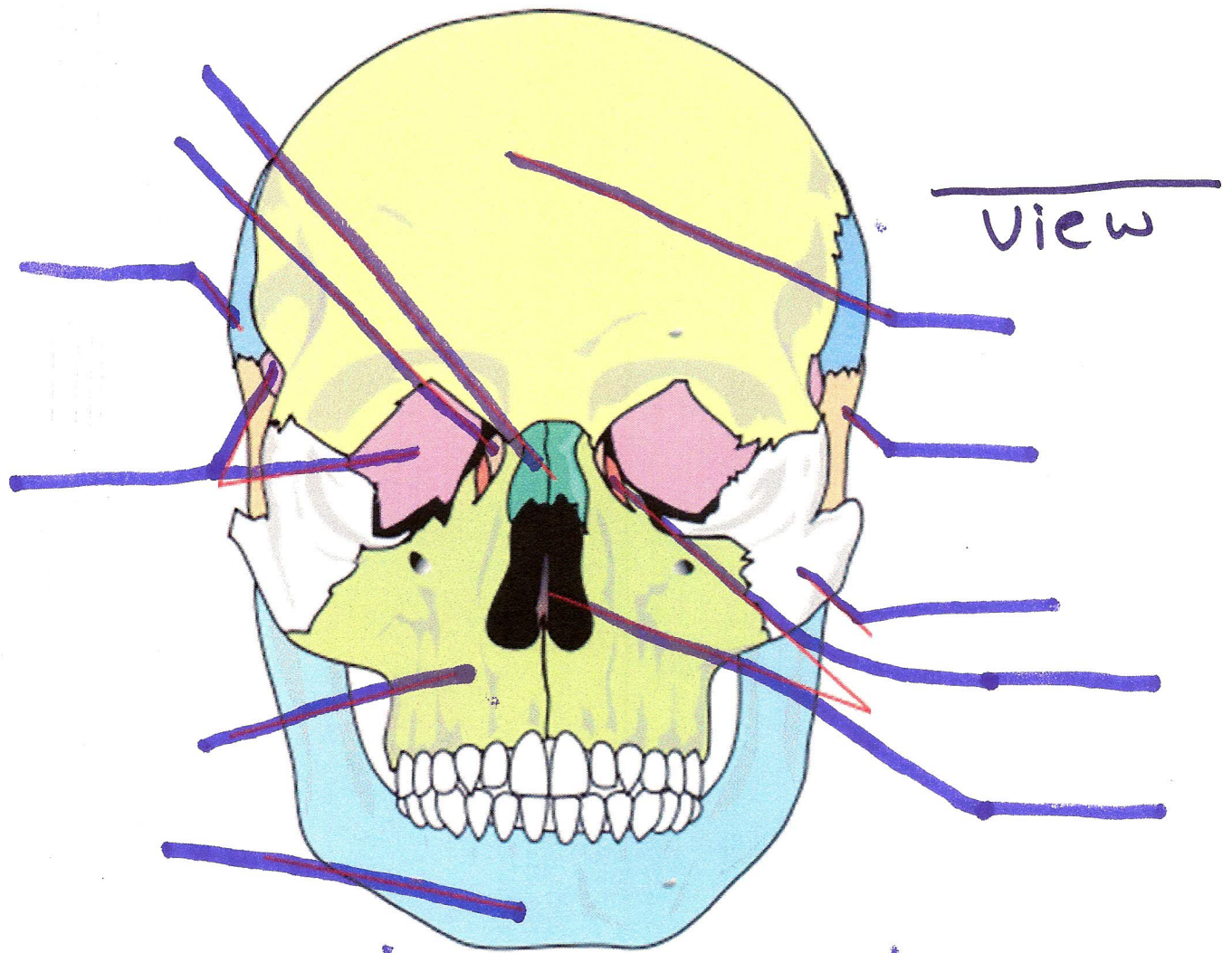


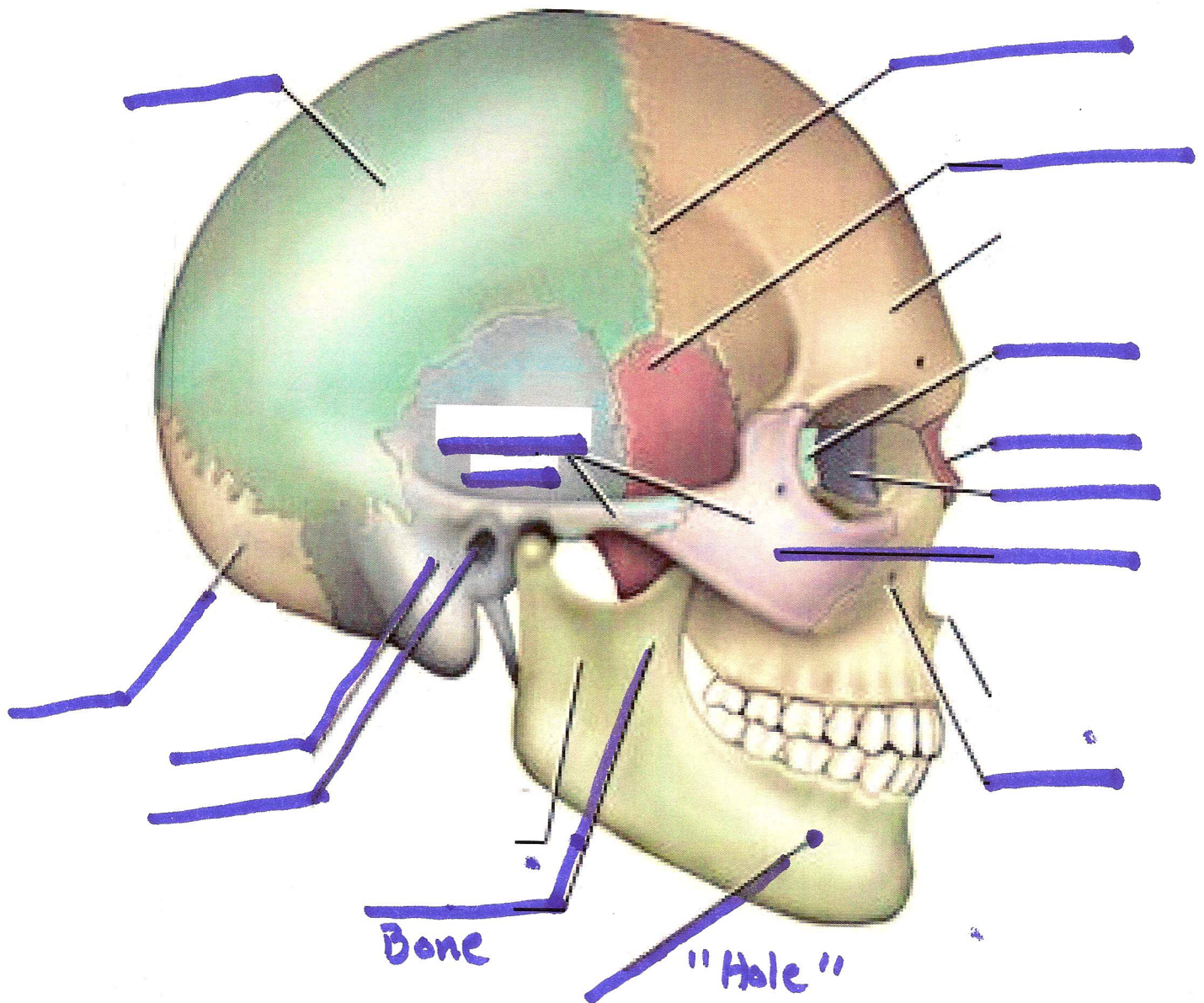
Axial Skeleton Study Guide



Label

Mandible	Nasal
Maxilla	frontal
Sphenoid	Temporal
Parietal	Zygomatic
Lacrimal	Ethmoid

View _____



Label

Occipital Bone

Temporal

external acoustic meatus

mandible

maxilla

Zygomatic Bone

Lacrimal

Nasal

Ethmoid

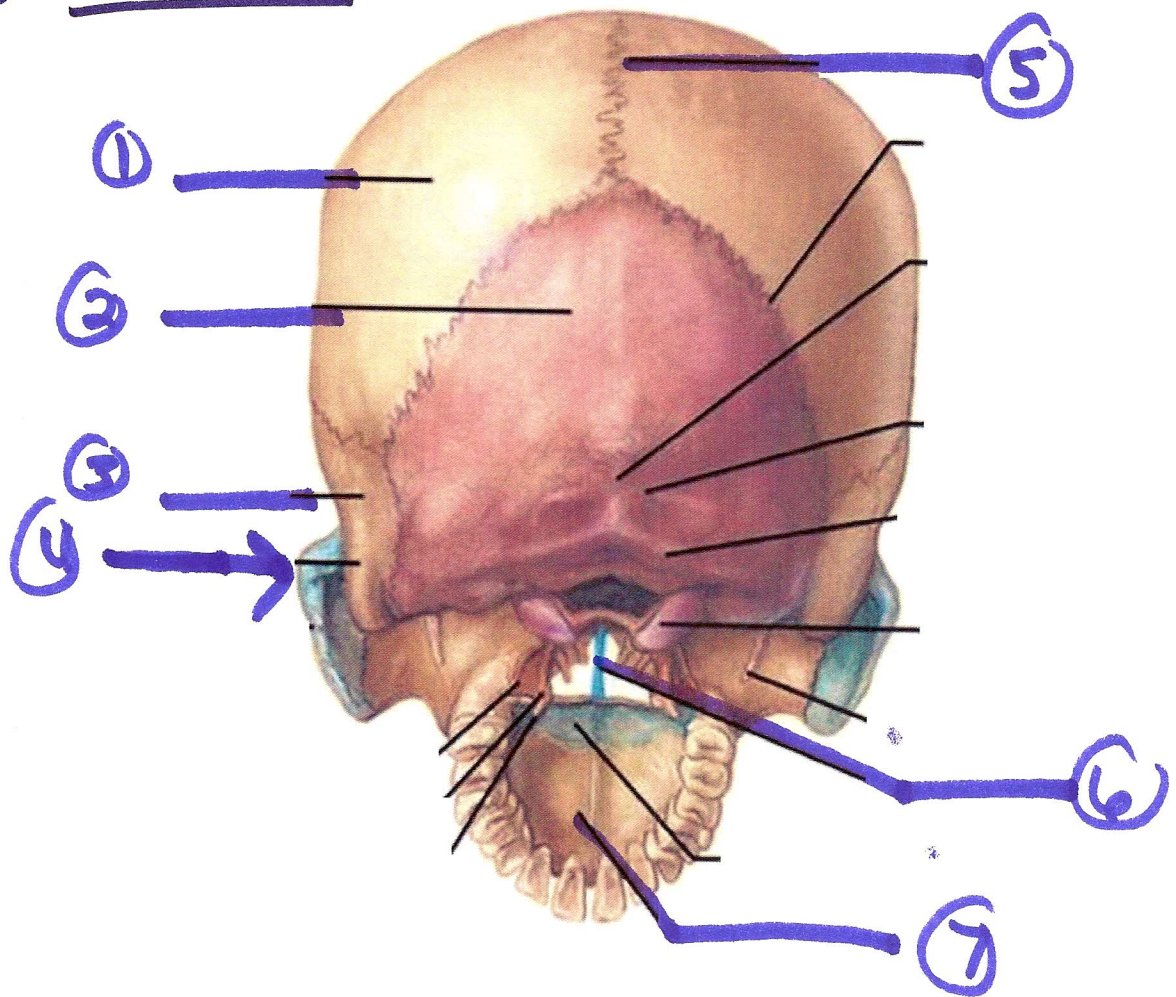
frontal

Coronal suture

Sphenoid Bone

mental foramen

View _____

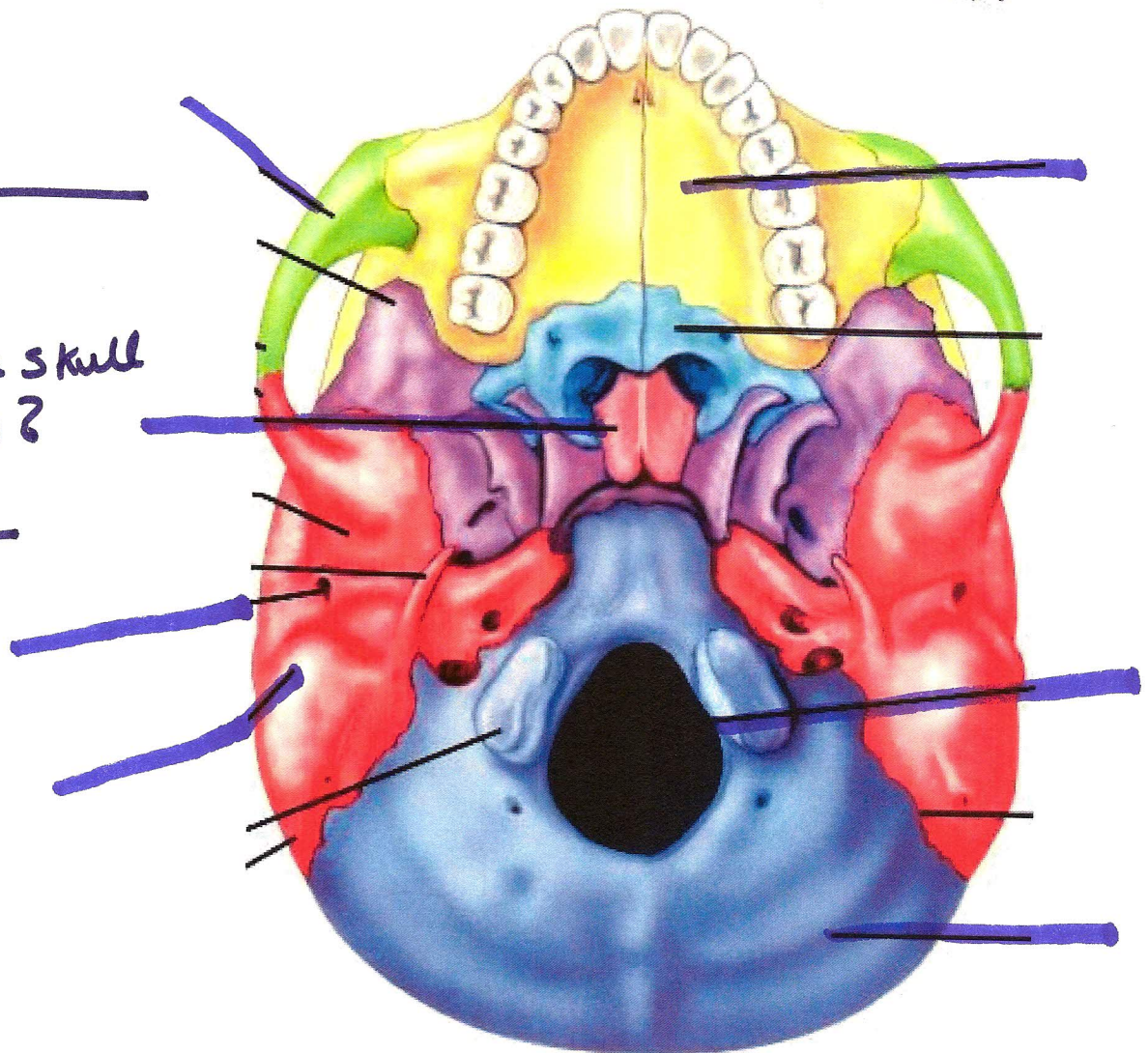


Label

parietal Bone
Sagittal suture
Occipital Bone
Temporal
Zygomatic
vomer
palate

View _____

What
part of the skull
is missing?



Label

Palate

Vomer

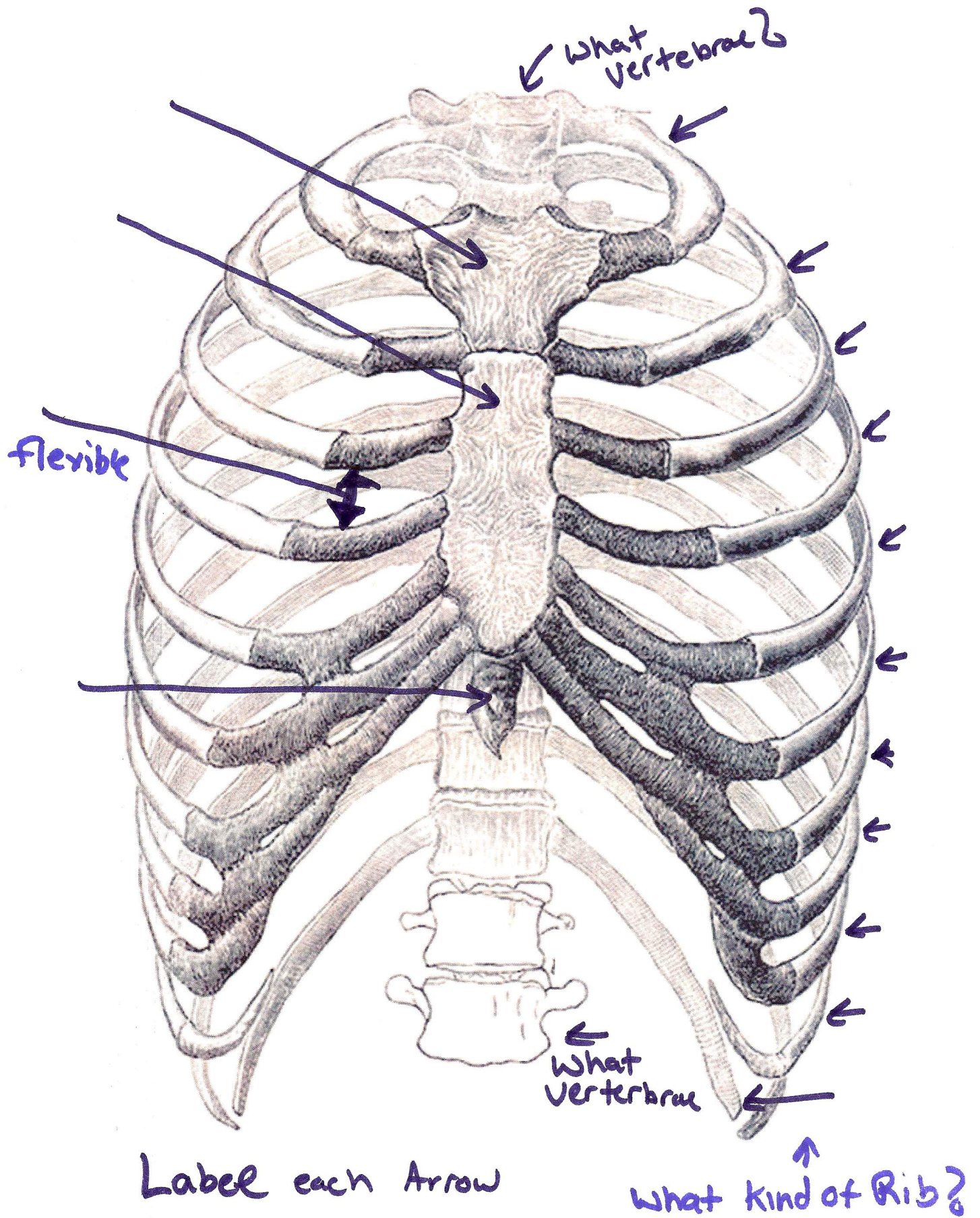
foramen magnum

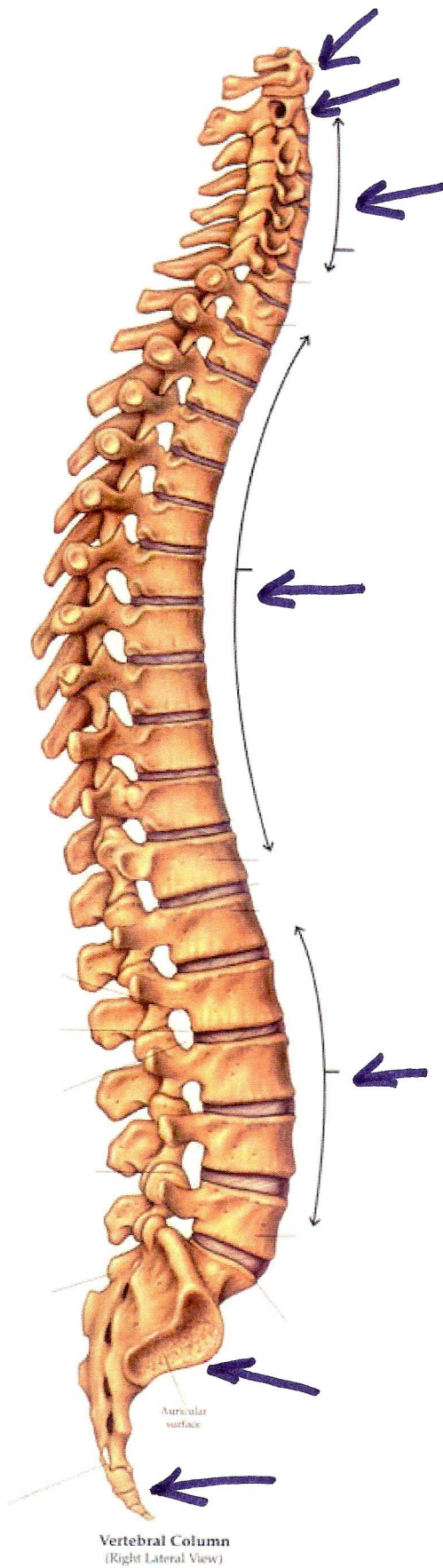
Occipital bone

Temporal bone

External Auditory meatus

Zygomatic
~~Sphenoid~~





How many of each Vertebrae

vertebrae	#